

## Original Article

# Accuracy between Functional Swallowing and Knebelman Craniometric Method to Measure Occlusal Vertical Dimension in Total Denture Wearers: A Quasi-experimental Study

Juan Huamani<sup>1</sup>, Romel Watanabe<sup>1</sup>, Jose Huamani<sup>2</sup>, Doris Salcedo-Moncada<sup>1</sup>, Daniel Alvitez-Temoche<sup>3</sup>, Frank Mayta-Tovalino<sup>4</sup>

<sup>1</sup>Department of Rehabilitative Stomatology, Faculty of Dentistry, Universidad Nacional Mayor de San Marcos, Lima, <sup>2</sup>School of Stomatology, Faculty of Health of Sciences, Universidad Privada San Juan Bautista, Ica, <sup>3</sup>Faculty of Dentistry, Universidad Nacional Federico Villarreal, Lima, <sup>4</sup>Postgraduate Department, CHANGE Research Working Group, Faculty of Health of Sciences, Universidad Científica del Sur, Lima, Peru

Received : 27-09-20  
Revised : 30-11-20  
Accepted : 21-12-20  
Published : 15-04-21

ABSTRACT

**Objective:** The objective was to determine the accuracy between functional swallowing (FS) and the Knebelman craniometric method (KCM) to measure occlusal vertical dimension (OVD) in total denture wearers. **Materials and Methods:** A quasi-experimental, prospective study was conducted considering the KCM diagnostic method as the gold standard compared to FS. All the totally edentulous patients attended at the School of Dentistry of the Universidad Nacional Mayor de San Marcos ( $n = 32$ ) in 2018–2019 were evaluated. Previous informed consent was obtained from all patients. A Knebelman's Craniometer was used to obtain longitudinal measurements measured in millimeters. The measurement was made with the Knebelman Craniometer by placing the tip into the external auditory canal inside the right meatus. On the other hand, for the FS method, the patients were seated comfortably with their back supported and their head in a natural position. Both upper and lower rollers were inserted into the mouth and the patient was instructed to swallow saliva for a period of 5 min. **Results:** When comparing the measurement of the OVD of KCM versus FS according to sex, men presented an OVD of  $68.1 \pm 3.9$  mm, being  $64.1 \pm 3.8$  mm in women. Accuracy was evaluated with an analysis of concordance between FS and the KCM in the determination of OVD in totally edentulous patients with a value of 0.97 (confidence interval = 0.31–0.99) ( $P = 0.013$ ). **Conclusions:** There is a good concordance between the FS method and the KCM at the time of determining the OVD of edentulous patients using total prostheses.

**KEYWORDS:** Accuracy, dentistry, occlusal vertical dimension, quasi-experimental study, total denture

## INTRODUCTION

Oral rehabilitation of a totally edentulous individual is one of the most complex treatments within prosthodontics because of the loss of various anatomical references such as tooth size, shape, and arrangement of the teeth in both jaws. In addition, esthetic and anatomical physiological alterations in the stomatognathic system must also be taken into account.<sup>[1-3]</sup>

Rehabilitation of total edentulousness requires the following of rigorous clinical stages. One of these stages is the determination and registration of vertical dimension, defined as the measurement of the height of the lower third of the face determined between two

**Address for correspondence:** Dr. Frank Mayta-Tovalino, Av. Paseo de la República 5544, Miraflores 15074, Peru. E-mail: [fmaytat@cientifica.edu.pe](mailto:fmaytat@cientifica.edu.pe)

This is an open access journal, and articles are distributed under the terms of the Creative Commons Attribution-NonCommercial-ShareAlike 4.0 License, which allows others to remix, tweak, and build upon the work non-commercially, as long as appropriate credit is given and the new creations are licensed under the identical terms.

**For reprints contact:** [reprints@medknow.com](mailto:reprints@medknow.com)

**How to cite this article:** Huamani J, Watanabe R, Huamani J, Salcedo-Moncada D, Alvitez-Temoche D, Mayta-Tovalino F. Accuracy between functional swallowing and Knebelman craniometric method to measure occlusal vertical dimension in total denture wearers: A quasi-experimental study. *J Int Soc Prevent Communit Dent* 2021;11:152-7.

Access this article online	
<b>Quick Response Code:</b> 	<b>Website:</b> <a href="http://www.jispcd.org">www.jispcd.org</a>
	<b>DOI:</b> <a href="https://doi.org/10.4103/jispcd.JISPCD_380_20">10.4103/jispcd.JISPCD_380_20</a>

arbitrarily selected and conventionally located points: the first in the upper maxilla (nasal or subnasal) and the second in the jaw (chin), coinciding at the midline.<sup>[4-7]</sup>

The occlusal vertical dimension (OVD) can be defined as a vertical measurement between two arbitrary points above and below the oral cavity in maximum intercuspation or contact.<sup>[5-8]</sup> This measurement can be reproduced for comparative purposes for clinical application. The determination of OVD is a critical stage in the success of total edentulous treatment without occlusal reference. It influences the esthetics, the anatomical functioning of the neuromusculature, and particularly the stability and masticatory efficacy of rehabilitation with total maxillomandibular prostheses.<sup>[8-11]</sup>

There are many techniques to determine the OVD including phonetic tests, preextraction diagnostic record, magnitude of the physiological inoculation space, harmony of the thirds of the face, harmony of the musculature for prosthetics, the swallowing test, and aspects of the facial furrows.<sup>[1-4]</sup> On the other hand, the null hypothesis was that there is no precision between the KMC and functional swallowing (FS) method. The magnitude of the OVD determined by conventional methods has been described as being superior to that of the Knebelman's craniometric method (KCM), and therefore, the aim of the present study was to compare the accuracy of FS and the KCM in the measurement of vertical dimension in total denture wearers.

## MATERIALS AND METHODS

### STUDY DESIGN AND PARTICIPANTS

A quasi-experimental, prospective study was conducted. A study of diagnostic techniques in occlusion was designed considering the KCM as the gold standard diagnostic test compared to the FS method. Patients were recruited from the School of Dentistry of the Universidad Nacional Mayor de San Marcos (UNMSM) in Lima-Peru. All the totally edentulous patients ( $n = 32$ ) of which 20 were men and 12 women attended during the period 2018–2019 were evaluated. Finally, the guidelines for reporting nonrandomized studies were followed in the preparation of this manuscript.

### INCLUSION AND EXCLUSION CRITERIA

Inclusion criteria were patients between 50 and 75 years of both sexes, bimaxillary total edentulous adult patients, patients without systemic disease that could prevent treatment, and patients who provided signed informed consent.

Exclusion criteria were partially edentulous patients (presence of a tooth), adult patients with the presence of flaccid mucosa not operable due to the presence of systemic disease, and patients' refusal to provide informed consent.

### CONFECTION OF WAX RIMS

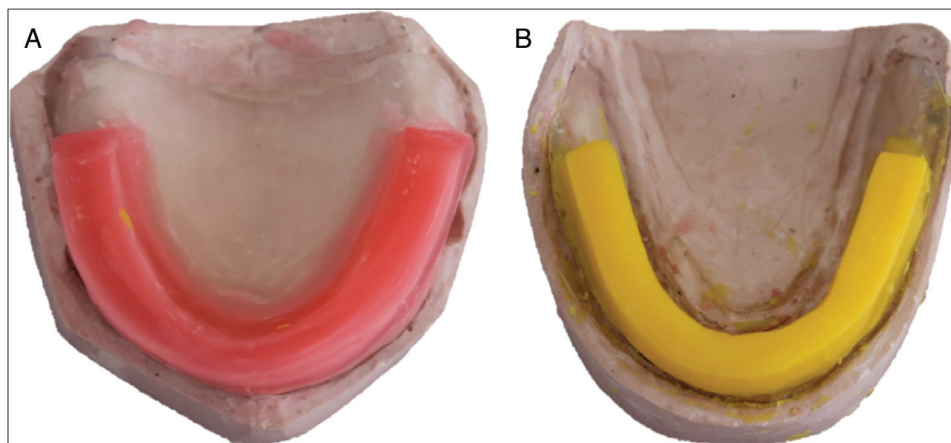
Base wax sheets (0335MO, Moyco, Dental Cost) were used to prepare the wax. The sheets were heated and rolled to gain the height of the impeller. It was placed over the edges of a previously made registration base. Pressure was then applied until it was parallel to the base of the correctly cut master model. The plaster spatula was heated and the impeller was made uniform both in contour and height to obtain the following average measurements: width of 5 mm and 8 mm in the vestibule–palatal direction in the anterior and posterior sector, respectively. Height of 22 mm measured from the bottom of the cleft created by the labial frenum and 12 mm from the registration base on the crest of the ridge in the area of the tuberosity with an inclination of 15° in the anterior sector. For the inferior impeller, we used yellow wax bars (SKU 3002 Dental, Coden Peru), and this impeller was later adapted for registration in the patient's mouth, evaluating adequate extension and stability of the same.

### ADAPTATION OF THE HEIGHT AND FACIAL CONTOUR

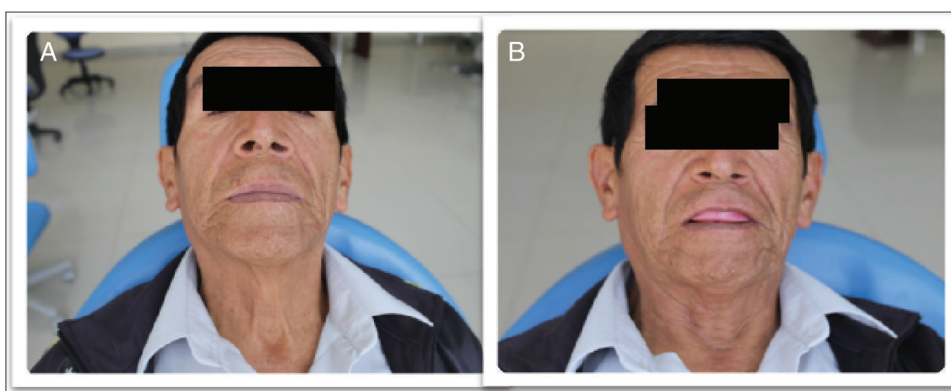
Once the height and contour impeller had been made on the upper registration base, it was tested and adapted in the patient to first, the facial contour, and then the height approximately 1 mm below the vermilion of the upper lip. A Fox plate (BM-VZB000550, Bio-Art, USA) was then used to determine the parallelism of the impeller which requires the anterior sector to be parallel to the bipupillary line and the posterior sector parallel to the Camper's plane. After achieving parallelism, the mid-face line, the canine line, and the smile line were marked on the impeller. In the lower jaw, the base plate was first tested to verify its stability. Once this was verified, the height and contour of the impeller were made using a yellow wax bar using anatomical structures such as the buccal commissure, lower lip vermilion, and the piriform papilla as references [Figure 1].

### DETERMINATION OF OCCLUSAL VERTICAL DIMENSION

All records were made by the same specialist in oral rehabilitation with the help of the dental assistant. FS method: Patients were seated comfortably with their back supported and their head in a natural position. Both upper and lower rollers were inserted into the mouth and the patient was instructed to swallow saliva for a period of 5 min [Figure 2]. KCM: The measurement was made with the Knebelman Craniometer (4718850,



**Figure 1:** Manufacture of upper and lower wax rims



**Figure 2:** Physiological method of swallowing

USA) by placing the tip into the external auditory canal inside the right meatus. Each patient was comfortably seated with the head in a natural position and then, with the help of the Knebelman Cranometer, measured with the tip in the external auditory canal and in the meatus, to finally slide the tip of the orbit to the lateral edge of the orbit. Afterward, the tragus in front of the external auditory canal was recorded with a point. With the tip comfortably inserted inside the meatus, the orbital tip was slid until reaching the lateral edge of the ocular orbit. With both the tips in position and without causing any discomfort, the fixation screw was firmly secured, thus determining the distance between the anterior wall of the ear canal and the outer corner of the eye, that is, the eye-ear distance [Figure 3].

**ETHICAL STATEMENT**

The research was reviewed by the Ethics Committee of the “Daniel Alcides Carrión” Institute of Tropical Medicine of the UNMSM CIEI-IMT “DAC” UNMSM-2018/01.

**STATISTICAL ANALYSIS**

Descriptive statistics were carried out by obtaining means and standard deviations of numerical variables.

For the evaluation of concordance, the intraclass correlation coefficient was used because both the methods were quantitative. Finally, a linear regression model was established to determine the predictor variables. The analyses were performed using Stata 15 software with a level of significance of  $P < 0.05$ .

**RESULTS**

When comparing the measurement of the OVD between the Knebelman’s craniometric method (KMC) and FS according to sex, men presented an OVD of  $68.1 \pm 3.9$  versus  $68.4 \pm 3.7$  mm, respectively, being  $64.1 \pm 3.8$  versus  $63.9 \pm 3.6$  mm in women. On the other hand, in relation to age, the largest OVD was presented in the elderly group with a KCM measurement of  $66.2 \pm 4.2$  mm, while younger adults presented the largest OVD measurement with  $64.7 \pm 4.4$  mm with the FS method [Table 1].

The accuracy of the two methods for determining the OVD was evaluated using concordance analysis, showing a value of 0.97 (confidence interval = 0.31–0.99;  $P = 0.013$ ) [Table 2 and Graph 1].

Linear regression analysis of the KCM and FS methods showed that only the covariable of sex was significant

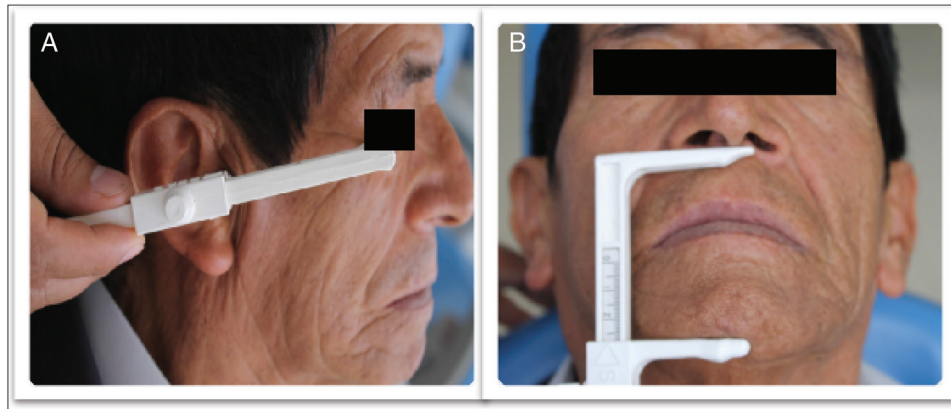


Figure 3: Knebelman craniometric method

**Table 1: Measurement of vertical dimension by functional swallowing and the Knebelman craniometric method on total denture wearers according to sex and age**

Variable	Mean±SD	
	KCM	PMS
Male	68.1±3.9	68.4±3.7
Female	64.1±3.8	63.9±3.6
Adult	64.1±4.3	64.7±4.4
Elderly	66.2±4.2	66.0±4.2

All measurements are in mmm. KCM=Knebelman’s craniometric method, PMS=Physiological method of swallowing, SD=Standard deviation

**Table 2: Analysis of the concordance between the physiological method of swallowing and the craniometric method of Knebelman**

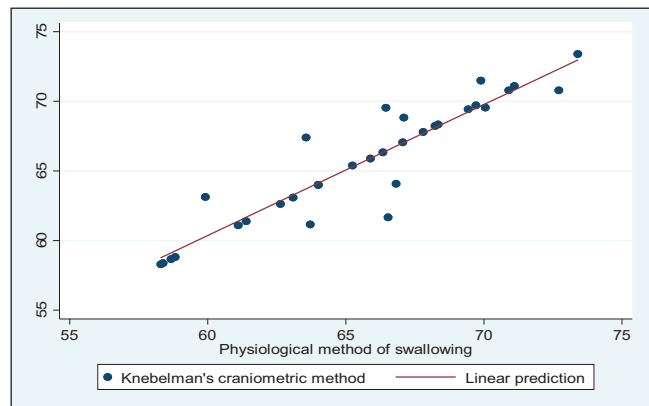
n	ICC	95% CI	P
32	0.97	0.31–0.99	0.013

CI=Confidence interval, 0.97

in the determination of OVD in totally edentulous patients with a  $P = 0.016$  and  $P = 0.003$ , respectively [Table 3].

## DISCUSSION

Considering the significant implications that OVD has on the functioning and esthetic outcomes of rehabilitation with removable prostheses in patients with total toothlessness or in those in whom the remaining teeth do not establish occlusal contact with the opposing arch, it is imperative to develop reliable and easy to use procedures for OVD measurement in clinical practice. The results of several studies have established that the KCM provides an almost optimal OVD in occlusal harmony and balanced occlusion in these patients.<sup>[12-17]</sup> Nonetheless, alternative methods that are both functional and easy to apply by general practitioners are needed. Therefore, the present study aimed to evaluate the FS method as an alternative



Graph 1: Correlation between the physiological method of swallowing and the craniometric method of Knebelman

to KCM in the Peruvian population and the null hypothesis was rejected based on the results obtained in the present study.

Comparison of the OVD with the two methods showed the measurement to be similar with an OVD of  $68.1 \pm 3.9$  mm with FS compared to  $68.4 \pm 3.7$  mm with KCM in men, with a similar close comparison of OVD in women. To date, no study has evaluated the OVD in a Peruvian population, and therefore, this study is important to develop a database of OVD measurements for planning clinical interventions including rehabilitation and providing better prosthesis functionality in totally toothless patients or in those with altered posterior support in Peru.

According to the study by Morata *et al.*,<sup>[2]</sup> age, sex, and type of the face influence the development of a predictive model using the distance between the eye and the right or left ear to determine OVD in toothed and toothless individuals. They concluded that the OVD depends on the sex and profile of the face and proposed a simple method to determine OVD using the eye–ear distance as an initial reference using a direct mathematical calculation.

**Table 3: Linear regression analysis between the physiological method of swallowing and the craniometric method of Knebelman**

Variables	Coefficient	SE	P	95% CI
Age	0.02	0.11	0.823	-0.20-0.25
Life stage	0.78	2.83	0.784	-5.01-6.57
KCM				
Sex	-3.81	1.48	0.016	-6.86--0.77
Cons	68.82	5.30	0.001	57.95-79.69
Age	0.06	0.10	0.570	-0.15-0.28
PMS				
Life stage	-0.96	2.69	0.724	-6.48-4.55
Sex	-4.53	1.41	0.003	-7.43--1.63
Cons	70.53	5.05	0.001	60.18-80.88

KCM=Knebelman's craniometric method, PMS=Physiological method of swallowing, CI=Confidence interval, SE=Standard error

On the other hand, Delić *et al.*<sup>[3]</sup> analyzed the relationships between craniometric points and the nasion-gnathion (N-Gn) distance. They found that the highest degree of correlation was observed between N-Gn and zygion-zygion distances. While these authors reported that the method cannot be considered totally reliable, it can be recommended because of its simplicity of applicability. Similarly, Chou *et al.*<sup>[5]</sup> stated that there is no ideal method for determining OVD in toothless patients. However, this study established the relationship between the ear, nose, and eyes to calculate the OVD, similar to the present study which showed that the eye-nose distance can be used to predict chin-nose distance with reasonable accuracy. Nonetheless, variables such as race and sex must also be taken into account.

On the other hand, as in the present study, Alhajj *et al.*<sup>[7]</sup> showed that the OVD is an integral step in prosthetic rehabilitation. So, it is very important to analyze the available methods for recording OVD because there is little evidence to support the clinical application of these techniques.

Another study by Alhajj and Daer<sup>[9]</sup> retrospectively evaluated the use of a skeletal linear distance approach to predict OVD. The results showed a positive correlation between the distances evaluated in men ( $P < 0.001$ ), while no significant correlation was found in women ( $P = 0.058$ ). They concluded that this may be an important measure to consider. According to Majeed *et al.*,<sup>[11]</sup> restoring the OVD is critical in full-mouth rehabilitation since an incorrect OVD affects the phonetics, esthetics, and function of the dentures. Therefore, the use of reproducible methods is necessary to ensure accurate OVD determination.

The main limitation of this research was that being a purely quasi-experimental study, it was not possible to randomize the sample studied due to the low incidence of bimaxillary totally edentulous patients. However,

the study design was that of a nonrandomized investigation that is also supported by the scientific literature. On the other hand, another limitation was that the OVD measurement was only made once because it was a clearly transversal study. Nonetheless, it is advisable to evaluate the OVD over time to observe how it is modified in totally edentulous patients with and without prosthetic rehabilitation.

Finally, with the results obtained in this research, we seek to determine the average vertical dimension of the Peruvian population since there are no studies conducted to determine the OVD and its relationship with bruxism in Peru.<sup>[18,19]</sup> In the absence of previous studies on the determination of OVD, the results of the present study provide a cornerstone for developing a database of OVD measurements in the Peruvian population. Correct OVD measurement produces better functionality of the prostheses in edentulous individuals. Further studies are needed to confirm our results.

## CONCLUSIONS

In summary, according to our results, there is a good concordance between the FS method and the KCM at the time of determining the OVD of edentulous patients using total prostheses.

## ACKNOWLEDGEMENT

The authors wish to thank the Faculty of Dentistry of the *Universidad Nacional Federico Villarreal*.

## FINANCIAL SUPPORT AND SPONSORSHIP

None to declare.

## CONFLICTS OF INTEREST

There are no conflicts of interest.

## AUTHORS CONTRIBUTIONS

Study conception (JH, RW, JH), data collection (JH, RW, JH), data acquisition and analysis (FMT, DSM,

DAT), data interpretation (FMT, RW, JH), and article writing (FMT, DSM, RW, DAT).

#### ETHICAL POLICY AND INSTITUTIONAL REVIEW BOARD STATEMENT

The research was reviewed by the Ethics Committee of the “Daniel Alcides Carrión” Institute of Tropical Medicine of the UNMSM CIEI-IMT “DAC” UNMSM-2018/01.

#### PATIENT DECLARATION OF CONSENT

All evaluated patients signed their informed consent to enter the study.

#### DATA AVAILABILITY STATEMENT

The data that support the study results are available from the author (Dr. Romel Watanabe, e-mail: [rwatanabev@unmsm.edu.pe](mailto:rwatanabev@unmsm.edu.pe)) on request.

#### REFERENCES

1. Farhad F. Determination of occlusal vertical dimension: A literature review. *J Prosth Dent* 1988;59:321.
2. Morata C, Pizarro A, Gonzalez H, Frugone-Zambra R. A craniometry-based predictive model to determine occlusal vertical dimension. *J Prosthet Dent* 2020;123:611-7.
3. Delić Z, Vukovojac S, Grzić R, Marčić D, Kovac Z, Kovacević D, *et al.* Evaluation of craniometric methods for determination of vertical dimension of occlusion – part 2. *Coll Antropol* 2003;27:191-4.
4. Delić Z, Šimunović-Šoškić M, Perinić-Grzić R, Vukovojac S, Rajić Z, Kuna T, *et al.* Evaluation of craniometric methods for determination of vertical dimension of occlusion. *Coll Antropol* 2000;24:31-5.
5. Chou T, Moore DJ, Young Jr. L, Glaros AG. A diagnostic craniometric method for determining occlusal vertical dimension. *J Prosthet Dent* 1994;71:568-74.
6. Fabbri G, Sorrentino R, Cannistraro G, Mintrone F, Bacherini L, Turrini R, *et al.* Increasing the vertical dimension of occlusion: A Multicenter retrospective clinical comparative study on 100 patients with fixed tooth-supported, mixed, and implant-supported full-arch rehabilitations. *Int J Periodontics Restorative Dent* 2018;38:323-35.
7. Alhaji MN, Khalifa N, Abduo J, Amran AG, Ismail IA. Determination of occlusal vertical dimension for complete dentures patients: An updated review. *J Oral Rehabil* 2017;44:896-907.
8. Helal MA, Hassan AH. Evaluation of lower facial heights as related to different anthropometric measurements in dentate and completely edentulous subjects. *Quintessence Int* 2016;47:51-60.
9. Alhaji MN, Daer AA. A proposed linear skeletal distance to predict occlusal vertical dimension: A cephalometric study. *J Prosthet Dent* 2017;118:732-5.
10. Geerts GA, Stuhlinger ME, Nel DG. A comparison of the accuracy of two methods used by pre-doctoral students to measure vertical dimension. *J Prosthet Dent* 2004;91:59-66.
11. Majeed MI, Haralur SB, Khan MF, Al Ahmari MA, Al Shahrani NF, Shaik S, *et al.* An anthropometric study of crano-facial measurements and their correlation with vertical dimension of occlusion among saudi arabian subpopulations. *Open Access Maced J Med Sci* 2018;6:680-6.
12. Basnet BB, Parajuli PK, Singh RK, Suwal P, Shrestha P, Baral D, *et al.* An anthropometric study to evaluate the correlation between the occlusal vertical dimension and length of the thumb. *Clin Cosmet Investig Dent* 2015;7:33-9.
13. Millet C, Jeannin C, Jaudoin P. Vertical dimensions in complete denture. *EMC-Odontologie* 2005;1:13-28.
14. Millet C, Leterme A, Jeannin C, Jaudoin P. Vertical dimension in the treatment of the edentulous patient. *Rev Stomatol Chir Maxillofac* 2010;111:315-30.
15. Tavano KT, Seraidarian PI, de Oliveira DD, Jansen WC. Determination of vertical dimension of occlusion in dentate patients by cephalometric analysis – pilot study. *Gerodontology* 2012;29:e297-305.
16. Miljkovic Z, Zeljkovic M, Anojcic M. Poredjenje fizioloskih metoda odrenjivanja visine zagrizaja kod bezubih osoba Comparison of physiologic methods of determination of occlusal vertical dimension in edentulous persons. *Vojnosanit Pregl* 2001;58:381-7.
17. de Souza RF, Marra J, Pero AC, Compagnoni MA. Effect of denture fabrication and wear on closest speaking space and interocclusal distance during deglutition. *J Prosthet Dent* 2007;97:381-8.
18. Alvítez-Temoche D, Calderón I, Ayala G, Watanabe R, Romero-Tapia P, Mayta-Tovalino F. Effectiveness of the increase of the occlusal vertical dimension in the smile of young Peruvian adults: A quasi-experimental study. *J Int Oral Health* 2020;12:197-202.
19. Marín M, Rodríguez Y, Gamboa E, Ríos J, Rosas J, Mayta-Tovalino F, *et al.* Level of work stress and factors associated with bruxism in the military crew of the peruvian air force. *Med J Armed Forces India* 2019;75:297-302.