

Vol 11 / Issue 6 / November-December 2021

Journal of International Society of Preventive & Community Dentistry

Publication of International Society of Preventive and Community Dentistry

JISPCD

www.jispcd.org

Evaluation of Buccal Bone Wall Thickness of Anterosuperior Teeth and Nasopalatine Duct Morphology in Cone Beam Computed Tomography of Patients Living at Different Altitudes: A Two-Year Retrospective Study

Nancy E. Córdova-Limaylla¹, José C. Rosas-Díaz¹, Rocío Alvarez-Medina¹, Jerson J. Palomino-Zorrilla¹, María E. Guerrero-Acevedo², Luis A. Cervantes-Ganoza³, Carlos López-Gurreonero⁴, César F. Cayo-Rojas¹

¹Academic Stomatology Program, Universidad Privada San Juan Bautista, Lima and Ica, Peru,

²Department of Medico Surgical Stomatology, Faculty of Dentistry, Universidad Nacional Mayor de San Marcos, Lima, Perú, ³Faculty of Stomatology and Investigation Institute, Universidad Inca Garcilaso de la Vega, Lima, Peru,

⁴Posgraduate School, “Grupo de Investigación Salud y Bienestar Global” and Faculty of Dentistry, Universidad Nacional Federico Villarreal, Lima, Peru

Received : 15-04-21
Revised : 22-06-21
Accepted : 30-06-21
Published : 30-11-21

ABSTRACT

Aim: To evaluate the buccal bone wall thickness of anterosuperior teeth and the dimension and morphology of the nasopalatine duct in cone beam computed tomography (CBCT) of patients treated in two cities at different altitudes.

Materials and Methods: In this retrospective analytical study, 79 CBCT scans were selected from a total of 347 in Juliaca, Peru (3824 m a.s.l.) and 171 CBCT scans were selected from a total of 622 in Lima, Peru (154 m a.s.l.). The buccal bone wall thickness of anterosuperior teeth was measured at 1 mm, 3 mm, and 5 mm from the alveolar crest. For the nasopalatine duct, its length and diameter were measured, and its anatomical shape was determined in coronal view. Descriptive statistical data such as mean and standard deviation were used, and Mann–Whitney U test was used for bivariate analysis. **Results:** When comparing the CBCT scans from both cities, significant differences were observed in buccal bone wall thickness at 3 mm and 5 mm from the alveolar crest ($P < 0.01$ and $P < 0.01$, respectively); for men, at 1 mm and 3 mm ($P = 0.04$ and $P = 0.04$); for the age group from 33 to 47 years, at 3 mm and 5 mm ($P < 0.01$ and $P < 0.01$); and for the age group from 48 to 77 years, at 1 mm ($P = 0.02$). Regarding the nasopalatine duct, significant differences were observed in women in relation to length and nasal opening diameter ($P < 0.01$ and $P < 0.01$) and for men, in length ($P < 0.01$); for the age group from 18 to 32 years, in all three levels ($P < 0.01$); for the age group from 33 to 47 years, in length and diameter of the oral opening ($P < 0.01$ and $P < 0.01$); and for the age group from 48 to 77 years, in length and diameter of the nasal opening ($P < 0.01$ and $P < 0.01$). The most frequent nasopalatine duct shape was a single canal with more than 66% of cases, according to sex and age group.

Conclusion: Patients living at different altitudes presented significant differences in buccal bone wall thickness according to sex and age; however, there were no differences related to dental inclination. Significant differences were found in the length and diameter of the nasopalatine duct at the nasal opening. In addition, the most frequent shape of the nasopalatine duct was the simple canal.

KEYWORDS: *Altitude, alveolar crest, bone wall, cone beam computed tomography, maxilla, nasopalatine duct*

Address for correspondence: Dr. César F. Cayo Rojas,

Academic Stomatology Program, Universidad Privada San Juan Bautista, Avenue s/n (Ex Hacienda Villa), Chorrillos, Lima, Peru.

E-mail: cesar.cayo@upsjb.edu.pe

This is an open access journal, and articles are distributed under the terms of the Creative Commons Attribution-NonCommercial-ShareAlike 4.0 License, which allows others to remix, tweak, and build upon the work non-commercially, as long as appropriate credit is given and the new creations are licensed under the identical terms.

For reprints contact: reprints@medknow.com

How to cite this article: Córdova-Limaylla NE, Rosas-Díaz JC, Alvarez-Medina R, Palomino-Zorrilla JJ, Guerrero-Acevedo ME, Cervantes-Ganoza LA, *et al.* Evaluation of buccal bone wall thickness of anterosuperior teeth and nasopalatine duct morphology in cone beam computed tomography of patients living at different altitudes: A two-year retrospective study. *J Int Soc Prevent Communit Dent* 2021;11:652-60.

Access this article online

Quick Response Code:



Website: www.jispcd.org

DOI: 10.4103/jispcd.JISPCD_126_21

INTRODUCTION

Implant placement is currently a treatment option for patients who are partially or fully edentulous. Diagnosis and treatment plan are key factors in achieving a successful outcome after implant placement and restoration. When evaluating a patient for dental implants, a complete dental history, photographs, study models, panoramic and periapical radiographs, and CBCT of the proposed implant sites should be considered.^[1] Treatment complications can lead to challenging clinical situations that can only be corrected with implant removal. In view of these potential complications, the morphology and dimensions of the bone structures in the anterosuperior region should be properly evaluated prior to dental implant placement.^[2]

The alveolar process is a tissue that is anatomically dependent on the tooth, as its size and thickness is conditioned by the eruption axis, inclination, and adjacent dental root morphology. This explains the atrophy of the alveolar process after tooth removal, as the greatest amount of bone loss occurs horizontally, mainly on the buccal side of the alveolar crest. Vertical bone loss also occurs, which is similarly more pronounced in the buccal region.^[3] After exodontia, the dentist faces the challenge of creating a prosthetic restoration that resembles the adjacent natural dentition. It has been suggested that a minimum width of 1–2 mm of buccal bone wall thickness is necessary to maintain a stable vertical dimension of the alveolar crest, as thin bone contributes to the risk of bone fenestration, dehiscence, and soft tissue recession.^[4,5]

Anatomical variations of the nasopalatine duct are documented in the literature presented as evaluation on CBCT images.^[6,7] Contact of the implant with nerve tissue may result in lack of osseointegration or lead to sensory impairment.^[8] Therefore, knowledge of normal appearance and anatomical variations in preoperative imaging is essential. With the introduction of CBCT, new diagnostic possibilities have been created in dentistry in order to improve the definitive diagnosis and to be able to choose the best treatment option that guarantees successful results on completion.^[9]

From the moment of conception, the growth and development of an individual depends on the interaction of genetics and environmental conditions. Humans living at altitudes higher than 2000 m above sea level have a decrease in the partial pressure of oxygen in the inspired air, causing a lower oxygen saturation in the hemoglobin, resulting in hypoxia, which, in order to compensate, requires certain adaptive mechanisms that favor the transport and use of oxygen at tissue level.^[10] To date (March 2021), no research has been reported

on bone characteristics of the anterosuperior region in people living at high altitude compared with people living at sea level. Currently available research refers to soft tissues, reporting wider gingival width in the anterosuperior tooth region, wider keratinized gingiva, smaller papillary gingival size, and greater gingival thickness in high-altitude residents compared with those living at sea level.^[11,12]

At Latin-American level, there are few data on the anatomical structures assessed in this study. It is necessary to have more data on the different populations, as these dimensions in the anterior maxilla are important for adequate planning and optimal results in implant treatment. Therefore, the present research aims at evaluating the buccal bone wall thickness of anterosuperior teeth and the morphology of the nasopalatine duct in CBCT of patients treated in two cities at different altitudes above sea level.

As a null hypothesis, it was considered that the thickness of the buccal bone wall of the upper anterior teeth and the morphology of the nasopalatine canal did not present significant differences in patients evaluated by CBCT, at different altitudes above sea level.

MATERIALS AND METHODS

BIOETHICAL CONSIDERATIONS

This research respected the bioethical principles of medical research involving human subjects of the Declaration of Helsinki related to confidentiality and non-maleficence. Informed consent was not required, as the study was retrospective; however, to ensure confidentiality, the data were coded and stored in an electronic device with a password to which only the principal investigator had access, and at the end of the study, the data were discarded. This research was approved by the Institutional Research Ethics Committee of the Universidad Peruana Cayetano Heredia, Peru (CI: 100504).

TYPE OF STUDY

Observational, retrospective, cross-sectional, and analytical study.

POPULATION AND SAMPLE SELECTION

The CBCT scans were taken in Peru, at the Imaxcenter Radiology Center in the city of Juliaca at an altitude of 3824 m a.s.l. and at the Panorol 3D Oral Radiology and Maxillofacial Tomography Center in the city of Lima at an altitude of 154 m a.s.l., during the years 2015 and 2016. Seventy-nine CBCT scans were selected out of a total of 347 in Juliaca, and 171 scans were selected out of a total of 622 in Lima. The sample size was calculated by using an average estimation formula with a finite population, considering $Z\alpha = 0.05$ (confidence

coefficient), a precision of 0.05, and a standard deviation (SD) of 0.257 and 0.390 for Juliaca and Lima, respectively. These values (SD) were obtained from a pilot study with 30 CT scans from both cities. The systematic random method was applied as a sampling technique, considering the following selection criteria:

Inclusion criteria

1. CBCT of patients with teeth in the anterosuperior sector.
2. CBCT of patients older than 18 years of age up to 77 years of age.

Exclusion criteria

1. CBCT of patients with signs of asymmetries and/or marked craniofacial alterations.
2. CBCT of patients with signs of maxillary bone pathologies.
3. CBCT of patients with signs of traumatic sequelae in the anterior maxillary region.
4. CBCT of patients with signs of previous surgical treatment in the anterior maxillary region.
5. CBCT of patients with rotated anterosuperior teeth.
6. CBCT of patients with restorative treatments (veneers, crowns, pins) that interfere with visualization.
7. CBCT of patients presenting anterosuperior teeth with a periodontal ligament width greater than 0.3 mm.

INTERVENING VARIABLES

The intervening variables considered in the study were sex, age, and dental inclination.

PROCEDURE

After requesting the corresponding permits from both imaging centers, the principal researcher of this study was trained in the use of the Ondemand Software (Cybermed, Korea) at the Panorax 3D Oral Radiology and Maxillofacial Tomography Center in the city of Lima. The training was conducted by a specialist in Oral and Maxillofacial Imaging with more than 10 years of experience. Subsequently, intraexaminer (NC) and interexaminer (NC and CT) calibration was performed with respect to the criteria for visualization of the anatomical shape (Kappa index = 0.98, 95% confidence interval [CI] = 0.92–1.00) and measurements of the nasopalatine duct (intraclass correlation coefficient [ICC] = 0.96, CI = 0.91–1.00) and measurements of the buccal alveolar bone of the anterosuperior teeth (ICC = 0.99, CI = 0.94–1.00).

The calibrated researcher performed the measurements on an OP 300 Maxio 3-in-1 tomographic equipment (Instrumentarium, Santa Catarina, Brazil), using an

Ondemand 3D APP + Cliniview software package, FOV = 13 × 15 cm. A maximum of 10 observations were made per day, over a period of five months. The same model and brand of CBCT equipment was used in both cities.

The following procedures were performed when evaluating each CBCT:

- A 1.5× Filter Tool was used.
- The axial axes of the teeth were determined in coronal, axial, and sagittal views and the buccal bone wall thickness was measured in sagittal view by using the Distance Measuring Tool.
- The buccal bone wall thickness measurement of the anterosuperior teeth included the periodontal ligament space and was determined with the distance in millimeters (mm) from the buccal side of the alveolar bone to the buccal side of the dental root. This was done at three levels: 1 mm, 3 mm, and 5 mm apical to the alveolar crest [Figure 1].
- The angle between the axis of the maxillary central incisor and the palatal plane (PP) was determined, and the teeth were divided into three groups according to this angle: palatal inclination group ($U1-PP \leq 110.1^\circ$), normal inclination group ($110.1^\circ < U1-PP \leq 121.5^\circ$), and buccal inclination group ($U1-PP > 121.5^\circ$).
- The axial axis of the nasopalatine duct was determined in coronal, axial, and sagittal views, and the dimensions of the duct were measured in sagittal view. To determine its dimensions, the distance in millimeters from the buccal edge of the nasopalatine duct to the palatal edge of the nasopalatine duct at the level of the nasal opening (diameter) and the distance in mm from the buccal edge of the nasopalatine duct to the palatal edge

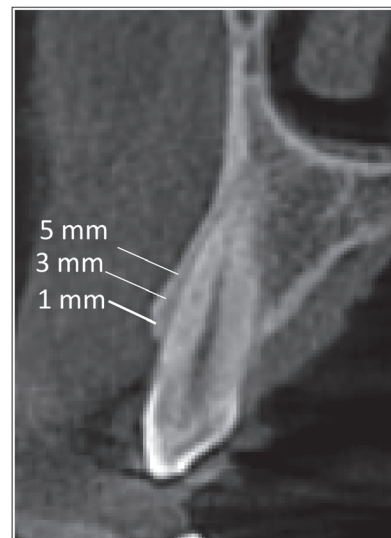


Figure 1: Buccal bone wall thickness measurement at 1, 3, and 5 mm from the alveolar crest

of the nasopalatine duct at the level of the oral opening (diameter) were measured; the length was determined by drawing a line from the midpoint of the diameter at the level of the oral opening to the midpoint of the diameter at the level of the nasal opening [Figure 2].

- Visualization of the anatomical shape of the nasopalatine duct was performed in a coronal view [Figure 3].

DATA ANALYSIS

Data were stored in an Excel 2013 spreadsheet (Microsoft, Redmond, WA) and subsequently imported by the statistical package SPSS (Statistical Package for the Social Sciences Inc. IBM, NY) 22.0. For the univariate analysis of categorical variables, a frequency table was prepared and for the numerical variables, measures of central tendency and dispersion were calculated. Before testing the hypothesis, a normality analysis was carried out on the quantitative data by using the Kolmogorov–Smirnov test. As no normal distribution of the data was found, nonparametric tests were used, such as the Mann–Whitney U test for two independent samples.

RESULTS

Regarding the dimension of buccal bone wall thickness according to the city of origin, a statistically significant difference was observed at the 5mm level ($P = 0.02$) and regarding the dimensions of the nasopalatine duct according to the city, statistically significant differences were observed with respect to the length of the nasopalatine duct ($P < 0.01$) and the diameter of the nasopalatine duct at the nasal opening level ($P < 0.01$) [Table 1].

When analyzing the buccal bone wall thickness, statistically significant differences were observed

between the city of Lima and Juliaca: for the female sex, at 3 and 5 mm ($P < 0.01$ and $P < 0.01$, respectively); and for the male sex, at 1 and 3 mm ($P = 0.04$ and $P = 0.04$, respectively) [Table 2].

When analyzing the nasopalatine duct, statistically significant differences were observed between the cities of Lima and Juliaca: for the female sex, with respect to length ($P < 0.01$) and diameter at the nasal opening level ($P < 0.01$); and for the male sex, only with respect to length ($P < 0.01$) [Table 2].

When analyzing the buccal bone wall thickness, statistically significant differences were observed between the city of Lima and Juliaca; for the age group from 33 to 47 years, at the level of 3 and 5 mm ($P < 0.01$ and $P < 0.01$, respectively); and for the age group from 48 to 77 years, only at the level of 1 mm ($P = 0.02$) [Table 3].

When analyzing the nasopalatine duct, statistically significant differences were observed between the city of Lima and Juliaca; for the age group from 18 to 32 years, in the three dimensions assessed ($P < 0.01$); for the age group from 18 to 32 years, in the three dimensions assessed ($P < 0.01$); for the age group from 48 to 77 years, only at the oral opening level ($P < 0.01$ and $P < 0.01$, respectively); and for the age group from 48 to 77 years, in the length and diameter at the nasal opening level ($P < 0.01$ and $P < 0.01$, respectively) [Table 3].

When analyzing the buccal bone wall thickness according to city and dental inclination, for both the right and left sides, no statistically significant differences were observed for the levels assessed at 1, 3, and 5 mm apical, with respect to the alveolar crest [Table 4].

Table 5 shows that the highest prevalence of the anatomical shape of the nasopalatine duct in both sexes was a simple canal, in both Lima and Juliaca.

Table 6 shows that the highest prevalence of the anatomical shape of the nasopalatine duct in all age groups was a simple canal, in both Lima and Juliaca.

DISCUSSION

In relation to buccal bone wall thickness, the results of the present research show that the bone in the anterosuperior sector is thin, with average values of 0.4–0.6 mm. These results agree with studies carried out by Braut *et al.*^[13] (Bern, Switzerland: 542 m a.s.l.), who assessed 125 CBCT and obtained an average between 0.5 and 0.7 mm. In their research, Januário *et al.*^[14] (Brasília, Brazil: 1172 m a.s.l.) used the same methodology as in the present one, for the measurement of the buccal bone wall thickness at three levels (1, 3, and 5 mm from the alveolar crest), and their average thickness was between 0.5 and 0.7 mm. Further,

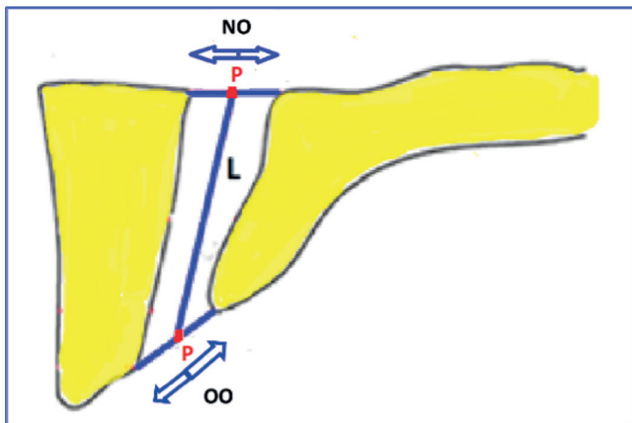


Figure 2: Nasopalatine duct dimensions. NO = diameter at nasal opening level; OO = diameter at oral opening level; L = nasopalatine duct length; P = middle point

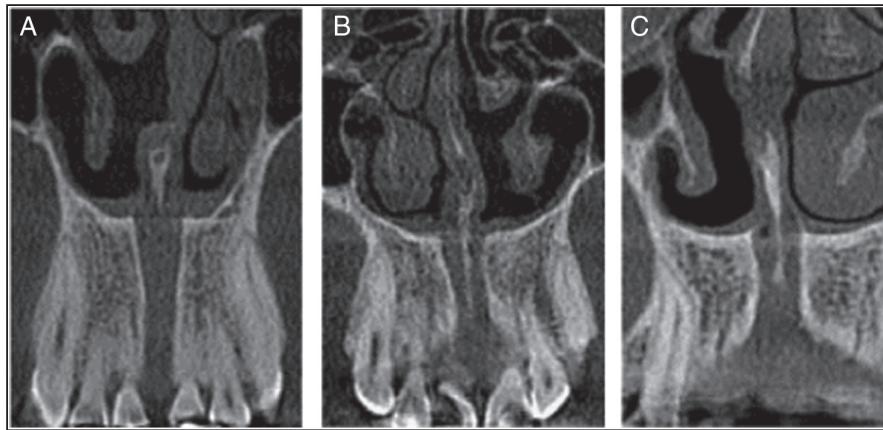


Figure 3: Coronal view of the anatomical shape of nasopalatine duct in Lima and Juliaca. (a) Single canal; (b) two parallel canals; (c) Y shape

Table 1: Comparison of the buccal bone wall thickness and nasopalatine duct, according to city of origin

Measurements	Distance to alveolar crest	Lima, X (SD)	Juliaca, X (SD)	P
Buccal bone wall thickness	At 1 mm	0.62 (0.32)	0.61 (0.31)	0.86
	At 3 mm	0.60 (0.41)	0.62 (0.39)	0.34
	At 5 mm	0.43 (0.38)	0.47 (0.39)	0.02*
Length of NPD		13.23 (2.35)	12.08 (2.37)	<0.01*
NPD diameter at NO		3.59 (1.69)	3.78 (1.31)	<0.01*
NPD diameter at OO		7.42 (2.09)	7.72 (2.48)	0.82

NO = nasal opening, NPD = nasopalatine duct, OO = oral opening, SD = standard deviation, X = mean

*The *P* value <0.05 is considered to be significant (Mann–Whitney U test)

El Nahass and Naiem^[15] (Cairo, Egypt: 23 m a.s.l.) assessed 73 CBCT and their results showed that the average thickness was between 0.6 and 0.8 mm.

Findings of the present research differ from the results reported by Huynh-Ba *et al.*,^[4] who assessed the buccal and palatal alveolar bone in 93 post-extraction sockets (incisors and premolars), using a caliper to measure at 1 mm apical to the alveolar crest. In their research of the anterior area (taking into account from canine to canine), the average buccal bone wall thickness was 0.8 mm, with this measurement being higher than the one obtained in the present study, probably due to the use of a different measuring instrument (clinical vs. CBCT). The study by Behnia *et al.*^[16] compared tomographic measurement with clinical measurement to determine the accuracy of CBCT; it concluded that CBCT often overestimates buccal and palatal bone thickness compared with direct measurement, but it has relatively good accuracy and reliability for measuring buccal bone wall thickness when this bone is greater than 1 mm. On the other hand, Vera *et al.*^[17] and Zekry *et al.*^[18] reported that CBCT showed an average buccal bone wall thickness in the anterior teeth of 0.8–0.9 mm, which is higher than that obtained in the present research, although these discrepancies may be due to the fact that the sample size used by these authors was smaller than the population evaluated in this study.

With respect to sex, it was observed that the buccal bone wall thickness in females was greater in the residents of Juliaca and was significant at levels of 3 and 5 mm apical to the alveolar crest. These results were probably due to the fact that women at high altitude experience different hormonal changes compared with women living at sea level (later menarche, delayed initial FSH release, earlier menopause).^[19,20] In males, buccal bone wall thickness was greater in male residents of Lima and was significant at levels of 1 and 3 mm apical to the alveolar crest. These findings may be due to the fact that in males a delay in sexual maturation at high altitude has been reported, which would indicate that at puberty the endocrine system is not altered, and thus there is less response of peripheral tissue to normal hormone concentrations.^[19]

In the present research, it was noticed that there is a tendency for the buccal bone wall thickness to decrease with increasing age, regardless of geographical altitude. This finding is consistent with the study by Wang *et al.*^[21] conducted on 300 patients with CBCT aged 18–60 years living at different altitudes from 5 to 1787 m a.s.l., and their results showed that with increasing age there is a statistically significant reduction in the buccal alveolar bone thickness, measured at a level of 4 mm apical to the cement-enamel junction (CEJ).

Table 2: Comparison of buccal bone wall thickness and nasopalatine duct dimensions by sex, according to city of origin

Measurements	Distance to alveolar crest	Sex					
		Female			Male		
		Lima, X (SD)	Juliaca, X (SD)	P	Lima, X (SD)	Juliaca, X (SD)	P
Buccal bone wall thickness	At 1 mm	0.61 (0.31)	0.64 (0.31)	0.09	0.63 (0.34)	0.56 (0.30)	0.04*
	At 3 mm	0.58 (0.41)	0.65 (0.40)	<0.01*	0.65 (0.42)	0.56 (0.36)	0.04*
	At 5 mm	0.40 (0.37)	0.49 (0.41)	<0.01*	0.47 (0.40)	0.44 (0.34)	0.79
Length of NPD		12.77 (2.19)	11.48 (2.08)	<0.01*	14.04 (2.39)	13.18 (2.48)	<0.01*
NPD diameter at NO		3.57 (1.81)	3.87 (1.24)	<0.01*	3.62 (1.49)	3.62 (1.40)	0.32
NPD diameter at OO		7.35 (2.08)	7.58 (2.58)	0.95	7.53 (2.09)	7.96 (2.25)	0.78

NO = nasal opening, NPD = nasopalatine duct, OO = oral opening, SD = standard deviation, X = mean

*The *P* value <0.05 is considered to be significant (Mann–Whitney U-test)

Table 3: Comparison of buccal bone wall thickness and nasopalatine duct dimensions by age, according to city of origin

Measurement	Distance to alveolar crest	Age								
		From 18 to 32			From 33 to 47			From 48 to 77		
		Lima, X (SD)	Juliaca, X (SD)	P	Lima, X (SD)	Juliaca, X (SD)	P	Lima, X (SD)	Juliaca, X (SD)	P
Buccal bone wall thickness	At 1 mm	0.63 (0.28)	0.65 (0.32)	0.37	0.60 (0.31)	0.65 (0.28)	0.08	0.62 (0.35)	0.54 (0.31)	0.02*
	At 3 mm	0.62 (0.39)	0.63 (0.40)	0.85	0.57 (0.37)	0.69 (0.40)	<0.01*	0.62 (0.46)	0.54 (0.37)	0.15
	At 5 mm	0.49 (0.38)	0.48 (0.39)	0.79	0.38 (0.33)	0.56 (0.44)	<0.01*	0.42 (0.42)	0.37 (0.30)	0.97
Length of NPD		12.91 (1.80)	11.90 (2.67)	<0.01*	13.95 (2.85)	12.46 (2.54)	<0.01*	12.93 (2.17)	11.91 (1.77)	<0.01*
NPD diameter at NO		3.35 (1.78)	3.80 (1.23)	<0.01*	3.94 (1.81)	3.81 (1.00)	0.49	3.50 (1.48)	3.73 (1.61)	<0.01*
NPD diameter at OO		7.05 (2.19)	7.85 (2.90)	<0.01*	7.76 (2.29)	7.49 (2.24)	<0.01*	7.44 (1.76)	7.78 (2.18)	0.09

NO = nasal opening, NPD = nasopalatine duct, OO = oral opening, SD = standard deviation, X = mean

*The *P* value <0.05 is considered to be significant (Mann–Whitney U-test)

In this study, with respect to the age groups and the buccal bone wall, greater thickness was observed in the population of Juliaca, in the age group from 33 to 47 years, being significant for the levels of 3 and 5 mm apical to the alveolar crest. This could be explained by the studies carried out by Choi *et al.*,^[22] who used 163 cases (17–83 years) with cephalometric monitoring over the years and indicated continuous growth of the craniofacial complex at all ages, with a rate of increase of 2%–10%. In addition, Manlove *et al.*^[23] found that up to the fourth decade there is continuous bone growth in both sexes, leading to an increase in cortical thickness and a maximum bone mass between 30 and 40 years of age, which means that the craniofacial skeleton continues to grow during adulthood.

Regarding tooth inclination, the results of the present research differ from those reported by Tian *et al.*,^[24] who assessed the buccal bone wall thickness in 45 patients aged 18–30 years at 10 levels along the root length from CEJ to the apex. They determined that for the first three levels from CEJ, the buccal inclination group showed higher thicknesses, followed by the normal

inclination group and finally the palatal inclination group. These discrepancies are apparently due to the ethnic differences in the populations studied, the larger number of CBCT scans evaluated, and the different age range, which was wider: 18–77 years.

The results also showed that the city of residence influences the buccal bone wall thickness with a tendency to be greater in the city of higher altitude, and this difference is significant at the level of 5 mm apical to the alveolar crest. It is known that there are physiological changes in residents at high altitude that lead to changes at the oral tissue level. Studies comparing populations at sea level and those at high altitude with respect to gingival biotype found that in residents at high altitude this biotype is thicker.^[11,12] It is known that the gingival biotype may be associated with the buccal alveolar bone thickness.^[25,26] Therefore, our results are in agreement with the findings of those investigations.

In relation to the nasopalatine duct, in the present research the dimensions of this duct were greater for

Table 4: Comparison of buccal bone wall thickness by dental inclination per side according to city of origin

Buccal bone wall thickness		Dental inclination								
		Palatal			Normal			Buccal		
		Lima, X (SD)	Juliaca, X (SD)	P*	Lima, X (SD)	Juliaca, X (SD)	P*	Lima, X (SD)	Juliaca, X (SD)	P*
Right side	At 1 mm	0.62 (0.31)	0.61 (0.31)	0.91	0.62 (0.32)	0.63 (0.31)	0.54	0.65 (0.32)	0.50 (0.31)	0.29
	At 3 mm	0.65 (0.47)	0.66 (0.42)	0.48	0.59 (0.40)	0.60 (0.38)	0.64	0.66 (0.42)	0.45 (0.26)	0.25
	At 5 mm	0.47 (0.44)	0.51 (0.43)	0.27	0.42 (0.36)	0.45 (0.36)	0.13	0.60 (0.49)	0.43 (0.23)	0.58
Left side	At 1 mm	0.62 (0.33)	0.62 (0.32)	0.89	0.62 (0.32)	0.62 (0.30)	0.67	0.56 (0.31)	0.50 (0.31)	0.62
	At 3 mm	0.63 (0.49)	0.66 (0.42)	0.18	0.60 (0.39)	0.59 (0.37)	0.99	0.55 (0.39)	0.45 (0.26)	0.68
	At 5 mm	0.45 (0.44)	0.49 (0.41)	0.07	0.42 (0.36)	0.45 (0.37)	0.20	0.48 (0.44)	0.43 (0.23)	0.82

X = mean, SD= standard deviation

*The P value <0.05 is considered to be significant (Mann–Whitney U-test)

Table 5: Anatomical shapes of the nasopalatine duct according to city and sex

City	Sex	Simple duct f (%)	Two parallel ducts f (%)	Y form f (%)	Total
Lima	Female	73 (67.59)	14 (12.96)	21 (19.44)	108 (100.0)
	Male	43 (68.25)	8 (12.70)	12 (19.05)	63 (100.0)
Juliaca	Female	38 (74.51)	7 (13.73)	6 (11.76)	51 (100.0)
	Male	21 (75.00)	6 (21.43)	1 (3.57)	28 (100.0)

f = absolute frequency

the city of Lima with respect to length and greater for the city of Juliaca with respect to the diameter at the nasal opening level. These results were different from those reported by other authors, such as Jornet *et al.*,^[27] Bornstein *et al.*,^[2] Thakur *et al.*,^[28] and Kajan *et al.*^[29] These discrepancies may be due to the diversity of populations studied by these authors, taking into account that there may be intervening factors, such as environment, race, and genetics, among others.^[11,12,25,26,28]

According to sex, males were found to have higher values compared with females for nasopalatine duct length, in agreement with the reports by Jornet *et al.*,^[27] Bornstein *et al.*,^[2] Thakur *et al.*,^[28] and Kajan *et al.*^[29] Regarding the diameter of the nasopalatine duct at the level of oral and nasal openings, it was found in this study that males had significantly larger values than females, which is consistent with reports by Panjnoush *et al.*,^[30] Salemi *et al.*,^[31] Khojastepour *et al.*,^[32] and Mishra *et al.*^[33]

Table 6: Anatomical shapes of nasopalatine duct by age group, according to city of origin

City	Age	Simple duct f (%)	Two parallel ducts f (%)	Y form f (%)	Total
Lima	From 18 to 32	39 (73.58)	4 (7.55)	10 (18.87)	53 (100.0)
	From 33 to 47	33 (63.46)	10 (19.23)	9 (17.31)	52 (100.0)
	From 48 to 77	44 (66.67)	8 (12.12)	14 (21.21)	66 (100.0)
Juliaca	From 18 to 32	18 (66.67)	8 (29.63)	1 (3.30)	27 (100.0)
	From 33 to 47	18 (72.00)	2 (8.00)	5 (20.00)	25 (100.0)
	From 48 to 77	23 (85.19)	3 (11.11)	1 (3.70)	27 (100.0)

f = absolute frequency

For anatomical shapes of the nasopalatine duct, the most prevalent shape was found to be the single canal, followed by the Y-shaped canal and two parallel canals. These results were similar to the studies reported by Bornstein *et al.*^[2] and Mishra *et al.*^[33]

The variations in buccal bone wall thickness and nasopalatine duct measurements at different geographical altitudes are based on the studies reported by Moore,^[34] Azad *et al.*,^[35] and Julian and Moore,^[36] as they report with respect to human physiology, that altitude produces a state of hypoxia, hemoglobin saturation, erythrocytosis, increased pulmonary diffusion capacity, increased tissue vascularization, increased number and density of circulatory capillaries, and increased capacity of cells to use oxygen, despite the low pressure. Another point to consider is growth influenced by genetic and nutritional factors, levels of habitual activity, and other

socioeconomic and environmental characteristics. Residents at high altitude have a one- to two-year growth delay, a less pronounced growth spurt, and adolescents growing for about two years longer, that is, up to 22 years of age. However, the adult height remains short.^[37,38] Meneses^[39] reported that Peruvian children in Cusco (3400 m a.s.l.) and Cerro de Pasco (4330 m a.s.l.) compared with children in Lima (154 m a.s.l.) are delayed in the onset of pubertal growth by a range of 8–18 months, with the peak of pubertal growth velocity occurring approximately at 1.5–2 years later in these cities.

The importance of this research lies in the fact that, based on the results obtained and being the only study in which these measurements are compared in populations living at different altitudes, treatment decisions can be made based on a comprehensive evaluation of the edentulous space before implant placement, in order to optimize surgical planning and avoid clinical complications in this region that presents high aesthetic demands.

One of the limitations of this research is that the population group was limited to a two-year evaluation period, and a longitudinal design was not applied, which does not allow a causal relationship to be established between geographical altitude and anatomical variations of the buccal bone wall thickness and the nasopalatine duct.

Further studies in high-altitude cities are recommended to corroborate the results obtained. Clinical and tomographic assessment of patients residing in high-altitude cities is also necessary to demonstrate whether there is a correlation between both methods for anatomical evaluation of the buccal bone wall thickness and the nasopalatine duct.

CONCLUSIONS

Considering the limitations of this research, it can be concluded that the buccal bone wall thickness was greater in people living at higher altitudes, with this difference being significant at a level of 5 mm apical to the alveolar crest. With respect to sex, the buccal bone wall thickness was greater in the male sex for the city of Lima and greater in the female sex for the city of Juliaca. In relation to age, statistically significant differences were found for the buccal bone wall thickness and the dimensions of the nasopalatine duct, with a tendency for the measurements to decrease with age. According to dental inclination, the greatest buccal bone wall thickness was in buccal inclination, followed by palatal inclination and finally normal inclination. However, these differences were not significant.

Regarding the nasopalatine duct, significant differences were found for the length (greater in the city of Lima) and diameter at the nasal opening (greater in the city of

Juliaca). For the dimensions of the nasopalatine duct according to sex, statistically significant differences were found, with higher values for the male sex. The most prevalent anatomical shape regardless of geographical altitude was the simple canal, followed by the “Y” shape and two parallel canals.

ACKNOWLEDGMENTS

The authors thank the San Juan Bautista Private University, Academic Stomatology Program, Lima, Peru, for their constant support in the preparation of this article.

FINANCIAL SUPPORT AND SPONSORSHIP

Nil.

CONFLICTS OF INTEREST

None to declare.

AUTHORS' CONTRIBUTIONS

They conceived the research idea (NECL), elaborated the article (NECL, CFCR, LACG), collected and tabulated the information (NECL, CFCR), carried out the bibliographic search (CLG, JCRD, MEGA, RAM), interpreted the statistical results, and helped in the development from the discussion (CFCR, JJPZ). They performed the critical revision of the article (NECL, JCRD, RAM, JJPZ, MEGA, CLG, LACG, CFCR). All the authors approved the final version of the article.

ETHICAL POLICY AND INSTITUTIONAL REVIEW BOARD STATEMENT

This research was approved by the Institutional Research Ethics Committee of the Universidad Peruana Cayetano Heredia, Peru (CI: 100504).

PATIENT DECLARATION OF CONSENT

Not applicable.

DATA AVAILABILITY STATEMENT

The data that support the study results are available from the author (e-mail: nancye.cordova@upsjb.edu.pe) on request.

REFERENCES

1. Block MS. Dental implants: The last 100 years. *J Oral Maxillofac Surg* 2018;76:11-26.
2. Bornstein MM, Balsiger R, Sendi P, von Arx T. Morphology of the nasopalatine canal and dental implant surgery: A radiographic analysis of 100 consecutive patients using limited cone-beam computed tomography. *Clin Oral Implants Res* 2011;22:295-301.
3. Couso-Queiruga E, Stuhr S, Tattan M, Chambrone L, Avila-Ortiz G. Post-extraction dimensional changes: A systematic review and meta-analysis. *J Clin Periodontol* 2021;48:126-44.
4. Huynh-Ba G, Pjetursson BE, Sanz M, Cecchinato D, Ferrus J, Lindhe J, *et al.* Analysis of the socket bone wall dimensions in the upper maxilla in relation to immediate implant placement. *Clin Oral Implants Res* 2010;21:37-42.
5. Chappuis V, Araújo M, Buser D. Clinical relevance of dimensional bone and soft tissue alterations post-extraction in esthetic sites. *Periodontol* 2000 2017;73:73-83.

6. Nasseh I, Aoun G, Sokhn S. Assessment of the nasopalatine canal: An anatomical study. *Acta Inform Med* 2017;25:34-8.
7. Bahşi I, Orhan M, Kervancioğlu P, Yalçın ED, Aktan AM. Anatomical evaluation of nasopalatine canal on cone beam computed tomography images. *Folia Morphol (Warsz)* 2019;78:153-62.
8. Shelley A, Tinning J, Yates J, Horner K. Potential neurovascular damage as a result of dental implant placement in the anterior maxilla. *Br Dent J* 2019;226:657-61.
9. Cayo-Rojas CF, Begazo-Jiménez LA, Romero-Solórzano LB, Nicho-Valladares MK, Gaviria-Martínez A, Cervantes-Ganoza LA. Periapical lesions and their relationship to Schneider's membrane in cone-beam computed tomography. *Int J Dent* 2020;2020:1-6.
10. Hoiland RL, Howe CA, Coombs GB, Ainslie PN. Ventilatory and cerebrovascular regulation and integration at high-altitude. *Clin Auton Res* 2018;28:423-35.
11. Alegre Y. Características gingivales de dos poblaciones a nivel del mar y en altura en la Facultad de Estomatología de la UIGV y en la carrera profesional de Estomatología de la UAC [tesis magister]. Lima: Universidad Peruana Cayetano Heredia; 2016. Available from: <https://repositorio.upch.edu.pe/handle/20.500.12866/596>. [Last accessed on Nov 15, 2020].
12. Alarcón M, Ramirez E, Liñán C. Periodontal biotype in two adolescent populations: A cross sectional study comparing, high altitude (4600 meters) vs. sea level (3 meters). *Clin Oral Implants Res* 2016;27:163.
13. Braut V, Bornstein MM, Belser U, Buser D. Thickness of the anterior maxillary facial bone wall—A retrospective radiographic study using cone beam computed tomography. *Int J Periodontics Restorative Dent* 2011;31:125-31.
14. Januário AL, Duarte WR, Barriviera M, Mesti JC, Araújo MG, Lindhe J. Dimension of the facial bone wall in the anterior maxilla: A cone-beam computed tomography study. *Clin Oral Implants Res* 2011;22:1168-71.
15. El Nahass H, Naiem SN. Analysis of the dimensions of the labial bone wall in the anterior maxilla: A cone-beam computed tomography study. *Clin Oral Implants Res* 2015;26:e57-61.
16. Behnia H, Motamedian SR, Kiani MT, Morad G, Khojasteh A. Accuracy and reliability of cone beam computed tomographic measurements of the bone labial and palatal to the maxillary anterior teeth. *Int J Oral Maxillofac Implants* 2015;30:1249-55.
17. Vera C, De Kok IJ, Reinhold D, Limpiphitanakorn P, Yap AK, Tyndall D, *et al.* Evaluation of buccal alveolar bone dimension of maxillary anterior and premolar teeth: A cone beam computed tomography investigation. *Int J Oral Maxillofac Implants* 2012;27:1514-9.
18. Zekry A, Wang R, Chau AC, Lang NP. Facial alveolar bone wall width—A cone-beam computed tomography study in Asians. *Clin Oral Implants Res* 2014;25:194-206.
19. von Wolff M, Nakas CT, Tobler M, Merz TM, Hilty MP, Veldhuis JD, *et al.* Adrenal, thyroid and gonadal axes are affected at high altitude. *Endocr Connect* 2018;7:1081-9.
20. Burtcher M, Gatterer H, Burtcher J, Mairböaurl H. Extreme terrestrial environments: Life in thermal stress and hypoxia. A narrative review. *Front Physiol* 2018;9:572.
21. Wang HM, Shen JW, Yu MF, Chen XY, Jiang QH, He FM. Analysis of facial bone wall dimensions and sagittal root position in the maxillary esthetic zone: A retrospective study using cone beam computed tomography. *Int J Oral Maxillofac Implants* 2014;29:1123-9.
22. Choi SH, Jung SN, Cha JY, Hu KS, Kim KD, Baik HS, *et al.* Changes in the craniofacial complex and alveolar bone height of young adults: Applications to dental medicine. *Clin Anat* 2016;29:1011-7.
23. Manlove AE, Romeo G, Venugopalan SR. Craniofacial growth: Current theories and influence on management. *Oral Maxillofac Surg Clin North Am* 2020;32:167-75.
24. Tian YL, Liu F, Sun HJ, Lv P, Cao YM, Yu M, *et al.* Alveolar bone thickness around maxillary central incisors of different inclination assessed with cone-beam computed tomography. *Korean J Orthod* 2015;45:245-52.
25. Joshi A, Suragimath G, Zope SA, Ashwinirani SR, Varma SA. Comparison of gingival biotype between different genders based on measurement of dentopapillary complex. *J Clin Diagn Res* 2017;11:ZC40-5.
26. Amid R, Mirakhori M, Safi Y, Kadkhodazadeh M, Namdari M. Assessment of gingival biotype and facial hard/soft tissue dimensions in the maxillary anterior teeth region using cone beam computed tomography. *Arch Oral Biol* 2017;79:1-6.
27. Jornet PL, Boix P, Perez AS, Boracchia A. Morphological characterization of the anterior palatine region using cone beam computed tomography. *Clin Implant Dent Relat Res* 2015;17(Suppl 2):e459-64.
28. Thakur AR, Burde K, Guttal K, Naikmasur VG. Anatomy and morphology of the nasopalatine canal using cone-beam computed tomography. *Imaging Sci Dent* 2013;43:273-81.
29. Kajan ZD, Kia J, Motevasseli S, Rezaian SR. Evaluation of the nasopalatine canal with cone-beam computed tomography in an Iranian population. *Dent Res J (Isfahan)* 2015;12:14-9.
30. Panjnoush M, Norouzi H, Kheirandish Y, Shamsiri AR, Mofidi N. Evaluation of morphology and anatomical measurement of nasopalatine canal using cone beam computed tomography. *J Dent (Tehran)* 2016;13:287-94.
31. Salemi F, Moghadam FA, Shakibai Z, Farhadian M. Three-dimensional assessment of the nasopalatine canal and the surrounding bone using cone-beam computed tomography. *J Periodontol Implant Dent* 2016;8:1-7.
32. Khojastepour L, Haghnegahdar A, Keshtkar M. Morphology and dimensions of nasopalatine canal: A radiographic analysis using cone beam computed tomography. *J Dent (Shiraz)* 2017;18:244-50.
33. Mishra R, Thimmarasa VB, Jaju P, Mishra R, Shrivastava A. Influence of gender and age on nasopalatine canal: A cone-beam computed tomography study. *J Dent Implant* 2017;7:15-9. Available from: <https://www.jdionline.org/text.asp?2017/7/1/15/225400>. [Last accessed on Feb 15, 2021].
34. Moore LG. Measuring high-altitude adaptation. *J Appl Physiol* (1985) 2017;123:1371-85.
35. Azad P, Stobdan T, Zhou D, Hartley I, Akbari A, Bafna V, *et al.* High-altitude adaptation in humans: From genomics to integrative physiology. *J Mol Med (Berl)* 2017;95:1269-82.
36. Julian C, Moore L. Human genetic adaptation to high altitude: Evidence from the Andes. *Genes (Basel)* 2019;10:150.
37. Yang W, Fu C, Su B, Ouyang C, Yang K. Child growth curves in high-altitude Ladakh: Results from a cohort study. *Int J Environ Res Public Health* 2020;17:3652.
38. Hoke M, Leatherman T. Secular trends in growth in the high-altitude district of Nuñoa, Peru 1964–2015. *Am J Phys Anthropol* 2019;168:200-8.
39. Meneses A. Influencia de la altitud geográfica y el estado nutricional sobre los indicadores de maduración esquelética en peruanos de 8 a 16 años de edad [Tesis Doctoral]. Lima: Universidad Peruana Cayetano Heredia; 2002. Available from: http://bibvirtual.upch.edu.pe:1701/permalink/f/1m9bev3/upch_aleph000029853. [Last accessed on Feb 12, 2021].